

### A NEW APPROACHES FOR DIAGNOSTIC OF CHRONIC OBSTRUCTIVE PULMONARY DISEASE

<sup>1</sup>Faculty of Medicine, Transilvania University of Brașov (Romania),

<sup>2</sup>Psychiatry and Neurology Hospital Brașov (Romania),

<sup>3</sup>University of Manchester (United Kingdom)

---

\*Antonella Cheșcă – Head of Imagistics Lab. at Lung Phthysiology Hospital (Brașov, Romania);

e-mail: anto.chesca@gmail.com

---

The present study refers to the exploration of the respiratory function of patients who presented acute symptoms of chronic obstructive pulmonary disease. In the medical specialty units, examination was performed using a standard chest X-ray imaging investigation; followed by a spirometry test, according to the patient's severity of symptoms, using the betamimetics test. Both the X-ray result and the imaging investigation of spirometry showed changes. Changes varied according to the patients from different investigate disease groups in relation to chronic obstructive pulmonary disease.

*Key words:* chronic obstructive pulmonary disease, chronic bronchitis, emphysema, standard chest X-ray, spirometry

---

Chronic obstructive pulmonary disease (COPD) has been defined by two American doctors – M. H. Williams and N. S. Seriff. COPD includes chronic disease, combining chronic bronchitis and emphysema, which causes breathing function problems affecting respiratory function with dyspnea. As a type of irreversible pathology, chronic obstructive pulmonary disease worsens over time and can lead to shallow breathing, impaired heart function, resulting in the eventual death of the patient. COPD caused by emphysema leads to chronic respiratory problems and has repercussions for cardiac function, including the risk of heart failure. Chronic bronchitis is represented by repeated outbursts of acute bronchitis for a period of time and with some seasonal exacerbation, leading to bronchitis with productive coughing accompanied by sputum. The pathophysiologic mechanism is represented, in this case, by inflammation of the bronchi and narrowing, which is caused by the symptoms described above. (9) Emphysema is characterized by impaired lung tissue and alveoli (the smallest components of the respiratory system, also called respirators bags), which are defining parts of the terminal bronchium respectively. Air locks at this level, causing shortness of breath; which is the common symptom of emphysema. The main cause in the occurrence of diseases that belong under the COPD category relate to smoking.

Thus, in context it is considered that both chronic bronchitis and emphysema are caused by long-term smoking by an individual. In addition to this, pollution and pollutants also represents a major cause in the development of COPD. For example, a form of emphysema, where an abnor-

mality on the proportions of enzymes in the lungs occurs – centrilobular emphysema – is regarded as a complication of chronic bronchitis, as a consequence of excessive smoking [9].

Given the risk factors associated with disease causation on the patient group which constitute COPD and in context with reference to spoil emphysema, it is considered important to take into account the emergence of diseases like tuberculosis or lung pneumoconiosis. To prevent the worsening of COPD, it is envisaged to reduce symptoms of respiratory function monitoring [3, 5]. For these patients, reducing or quitting smoking is advisable for preventing the occurrence of acute respiratory disease, as well as receiving appropriate treatment to address the symptoms of acute respiratory illness [8]. The treatment is suitable when diagnosing chronic bronchitis or lung emphysema. With treatment methods, besides the mandatory specific medication administered to the patient, including bronchodilators, patient care is based on the symptoms including the respiratory inhalation of oxygen [2, 7]. Of course medical treatments including bronchodilators are administered strictly on an individualized patient basis, according to the severity of symptoms [10]. From this point of view, such treatments involve applying the principles of personalized medicine [1, 12].

In order to establish an adequate health behavior following a correct treatment, it is necessary that medical specialty undertake a standard chest X-ray and exploration by performing spirometry lung function. Standard chest radiographs reflect changes that may occur in the group of diseases that constitute COPD and spi-

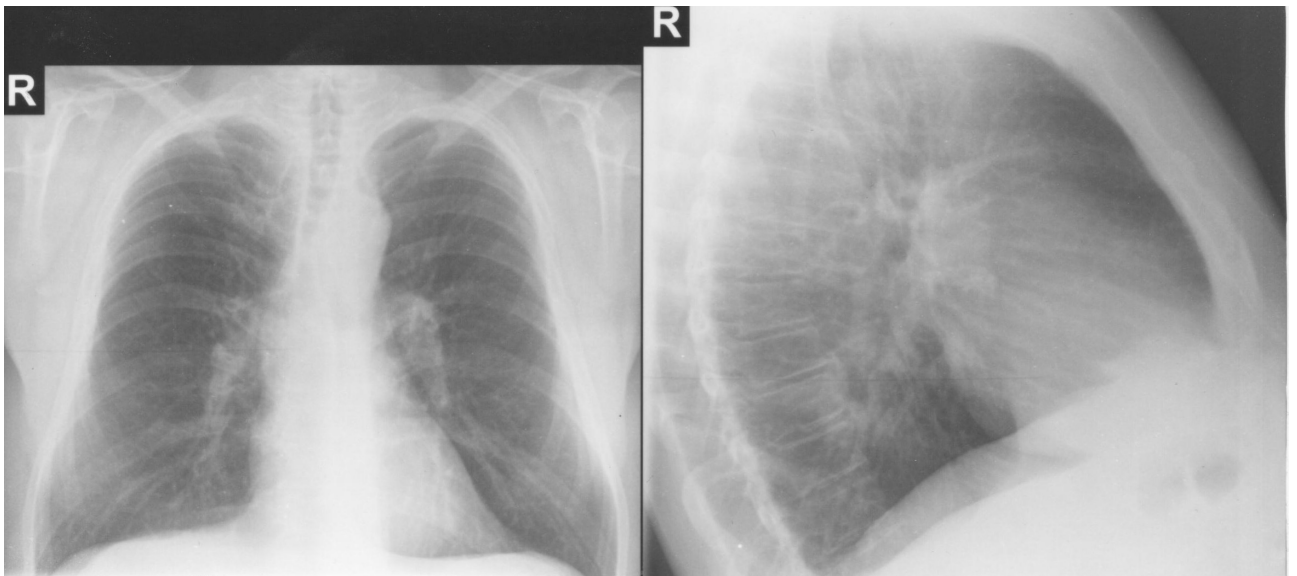

Figure 1 – Chest X-ray

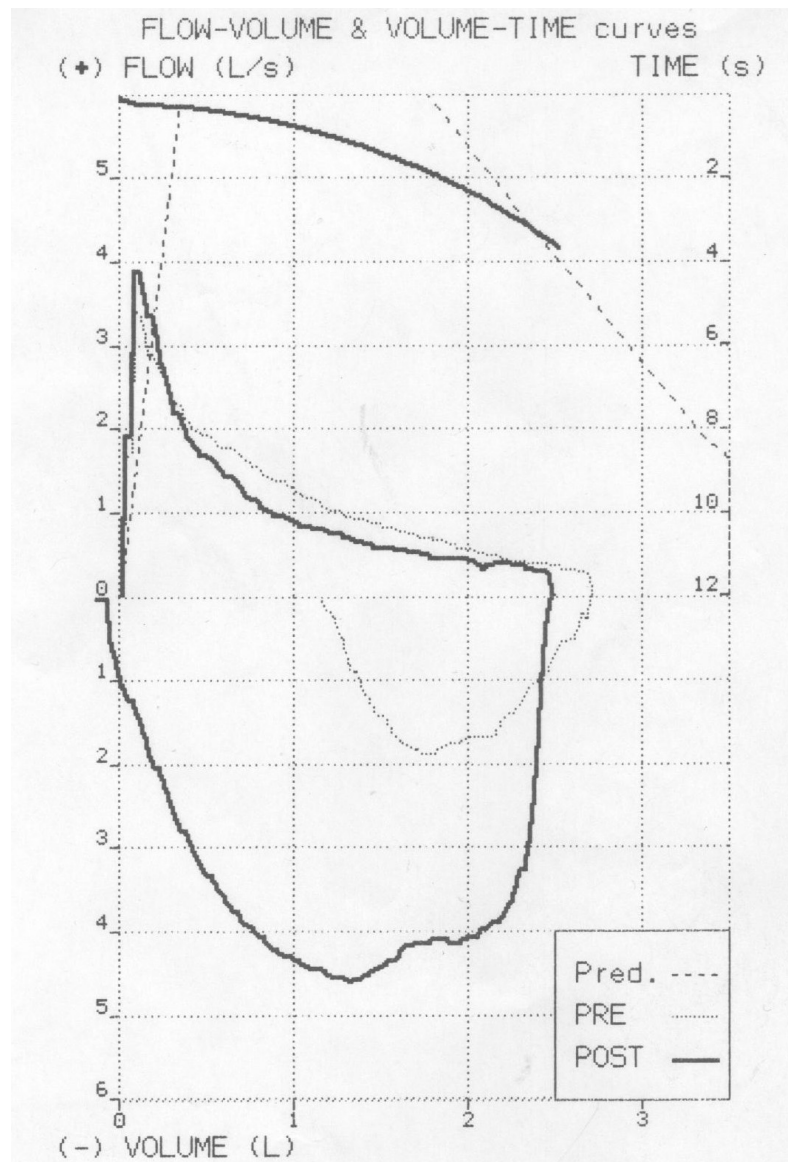


Figure 2 – Spirometry

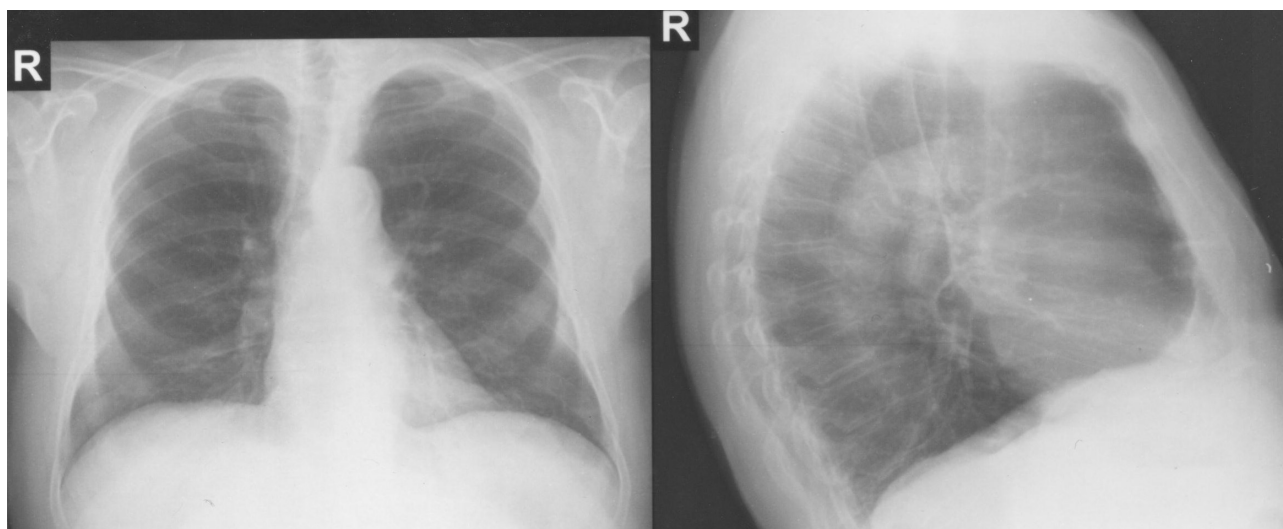


Figure 3 – Chest X-ray

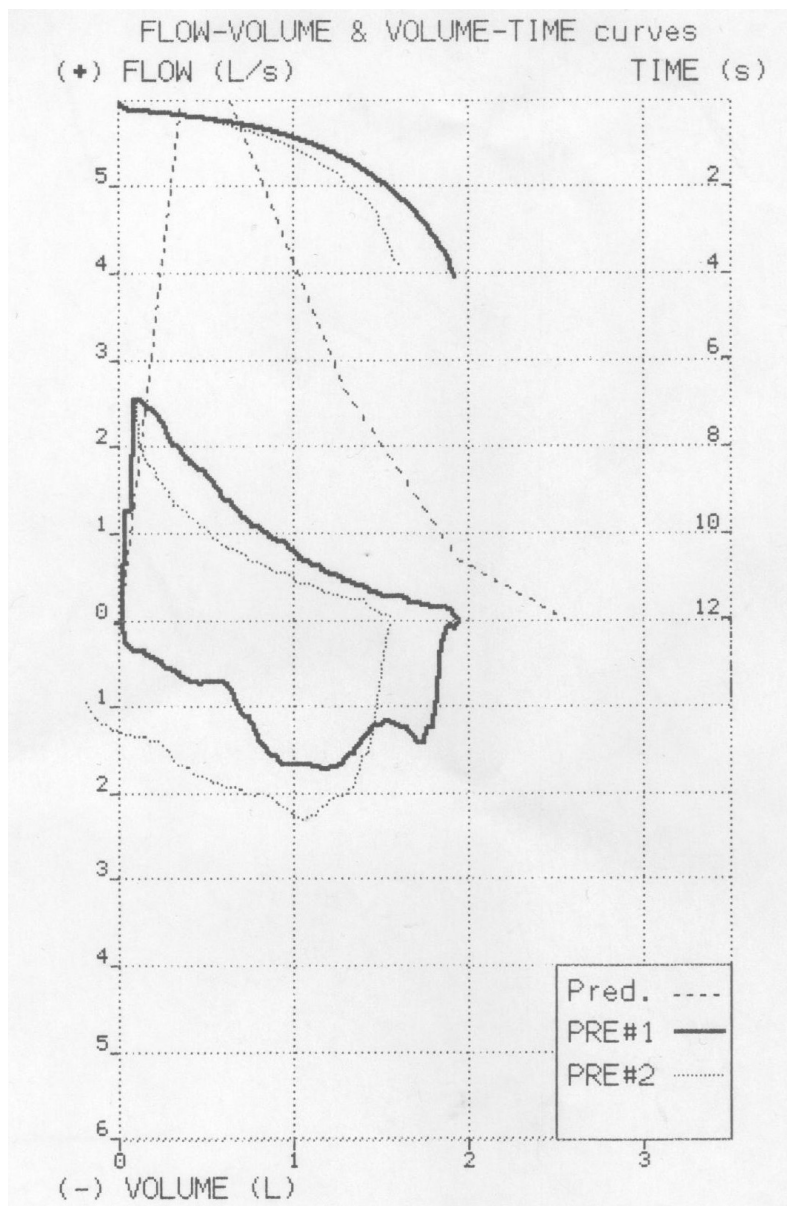


Figure 4 – Spirometry

rometry performed in basal condition or test substances betamimetics, allows for the degree of bronchial obstruction to be assessed through review of the characteristic curve together with adjusting the those settings involved in respiratory function testing [4].

#### MATERIAL AND METHODS

For this study a group of 10 patients were selected. The patients were presented to a medical unit specialized for treat pulmonary diseases. The patients had been diagnosed with respiratory symptoms classed as diseases relating to COPD. The patients were examined using imaging produced from standard chest X-ray followed by spirometry tests to observe obstructive changes in respiratory function. Standard chest X-rays were performed using *Swissray ddR* apparatus; spirometry was performed using a spirometer *Microlab III* model.

#### RESULTS AND DISCUSSION

From the study group, data from two representative patients is presented: one with chronic bronchitis and the other with emphysema. The first selected patient was male, from an urban home environment. This patient was presented to a physician for shortness of breath, cough with sputum production, and having known chronic bronchitis. Radiological examination and spirometry were suggestive of this condition (fig. 1, 2).

The second patient was also male, from an urban home environment. This patient was referred to a physician for dyspnea with suffocation, and a dry cough. Chest radiography and spirometry were performed. The results show changes consistent with pulmonary emphysema (fig. 3, 4).

#### CONCLUSION

The groups of diseases that belong to COPD require strict monitoring. In this context, the practical application of methods for informing the general population about the seriousness of repeated exacerbation of bronchitis, respiratory symptoms are important. Depending upon seasonal patterns these conditions can lead to serious types of respiratory diseases, such as chronic bronchitis or emphysema. Moreover, the public must be informed of the risk factors that lead to diseases related to occurrences of diseases related to COPD pathology group, such as smoking.

With patients with symptoms of chronic bronchitis or emphysema, correct diagnosis is important. This is so medical personnel can proceed with the application proper treatment; this is necessary in order to reduce rates of morbidity and mortality. In this paper, we have presented two case studies relating to patients with chronic

bronchitis and emphysema. Through conducting X-rays and spirometry tests we have provided representative images and commentary, designed to lay down a benchmark that can assist medical professionals in making a more accurate and early diagnosis of these serious conditions.

#### REFERENCES

- 1 Baker W. L. Pharmacologic treatments for chronic obstructive pulmonary disease: a mixed-treatment comparison meta-analysis /W. L. Baker, E. L. Baker, C. I. Coleman //Pharmacotherapy. – 2009. – V. 29(8). – P. 891-905.
- 2 Chen A. M. Long-acting bronchodilator therapy for the treatment of chronic obstructive pulmonary disease /A. M. Chen, S. G. Bollmeier, P. M. Finnegan //Ann. Pharmacother. – 2008. – V. 42(12). – P. 1832-1842.
- 3 Ciappi G. Functional diagnosis of chronic obstructive pulmonary disease /G. Ciappi, G. Corbo, S. Valente //Ann. Ist. Super. Sanita. – 2003. – V. 39(4). – P. 529-547.
- 4 Cooper C. B. Primary care of the patient with chronic obstructive pulmonary disease-part 4: understanding the clinical manifestations of a progressive disease /C. B. Cooper, M. Dransfield //Am. J. Med. – 2008. – V. 121. – P. 33-45.
- 5 Hurst J. R. Management and prevention of chronic obstructive pulmonary disease exacerbations: a state of the art review /J. R. Hurst, J. A. Wedzicha //BMC Med. – 2009. V. 7. – P. 40.
- 6 Izumi T. Definition of chronic obstructive disease //Nihon Rinsho. – 2003. – V. 61(12). – P. 2058-2070.
- 7 Puhan M. A. drugs to reduce exacerbations in patients with chronic obstructive pulmonary disease: a network meta-analysis /M. A. Puhan, L. M. Bachmann, J. Kleijnen //BMC Med. – 2009. – V. 7. – P. 2.
- 8 Reddy C. B. Is combination therapy with inhaled anticholinergics and beta2-adrenoceptor agonists justified for chronic obstructive pulmonary disease? /C. B. Reddy, R. E. Kanner //Drugs Aging. – 2007. – V. 24(8). – P. 615-628.
- 9 Romagnoli M. Chronic obstructive pulmonary disease: definition and classification of severity /M. Romagnoli, L. M. Fabbri //Ann. Ist. Super Sanita. – 2003. – V. 39(4). – P. 461-466.
- 10 Sethi S. Bronchodilator combination therapy for the treatment of chronic obstructive pulmonary disease /S. Sethi, C. Cote //Curr. Clin. Pharmacol. – 2011. – V. 6(1). – P. 48-61.
- 11 Yoshida M. General concepts and the history of chronic obstructive pulmonary disease //Nihon Kyobu Shikkan Gakkai Zasshi. – 1990. – V. 28(3). – P. 390-398.

12 Yu T. Support of personalized medicine through risk-stratified treatment recommendations – an environmental scan of clinical prac-

tice guidelines /T. Yu, D. Vollenweider, R. Varadhan //BMC Med. – 2013. – V. 11. – P. 7.

Received 05.07.2021

А. Ческа<sup>1</sup>, С. А. Ческа<sup>2</sup>, Т. Сэндл<sup>3</sup>

### НОВЫЕ ПОДХОДЫ К ДИАГНОСТИКЕ ХРОНИЧЕСКОЙ ОБСТРУКТИВНОЙ БОЛЕЗНИ ЛЕГКИХ

<sup>1</sup>Факультет медицины университета Трансильвании Брашов (Румыния);

<sup>2</sup>Госпиталь психиатрии и неврологии Брашов (Румыния),

<sup>3</sup>Университет Манчестера (Великобритания)

---

\*Антонелла Ческа – руководитель лаборатории визуальных методов, Больница фтизиатрии легких (Брашов, Румыния); электронная почта: anto.chesca@gmail.com

---

В представленной статье описан подход к исследованию дыхательной функции пациентов с острыми симптомами хронической обструктивной болезни легких. В специализированных медицинских отделениях было проведено обследование пациентов с использованием стандартного рентгенологического исследования грудной клетки с последующим использованием спирометрии в зависимости от тяжести симптомов пациента, с помощью теста бетамиметики. В результате как рентгенологическое исследование, так и спирометрия показали изменения в дыхательной функции пациентов, которые варьировались в зависимости от группы, в которую входили пациенты с хронической обструктивной болезнью легких.

*Ключевые слова:* хроническая обструктивная болезнь легких, хронический бронхит, эмфизема, стандартная рентгенография грудной клетки, спирометрия

А. Ческа<sup>1</sup>, С. А. Ческа<sup>2</sup>, Т. Сэндл<sup>3</sup>

### ӨКПЕНІҢ СОЗЫЛМАЛЫ ОБСТРУКТИВТІ АУРУЛАРЫН ДИАГНОСТИКАЛАУҒА КӨЗҚАРАС

<sup>1</sup>Трансильвания Брашов (Румыния) университетінің медицина факультеті;

<sup>2</sup>Брашов (Румыния) университетінің психиатрия және неврология госпиталі,

<sup>3</sup>Манчестер университеті (Ұлыбритания)

---

\*Антонелла Ческа – Imagistics зертханасының меңгерушісі. Өкпенің фтизиатриялық ауруханасында (Брашов, Румыния); электрондық поштасы: anto.chesca@gmail.com

---

Ұсынылған мақалада өкпенің созылмалы обструктивті ауруының өткір симптомдарымен науқастардың тыныс алу функцияларын зерделеудің көзқарасы сипатталған. Арнайы медициналық бөлімшелерде одан әрі пациент симптомдарының ауырлығына байланысты бетамиметика тестінің көмегімен спирометрияны пайдаланумен кеуде клеткасын стандартты рентгенологиялық тексеруді қолдану арқылы науқастарды тексеру жүргізілген. Нәтижесінде рентгенологиялық зерттеу де, спирометрия да пациенттердің тыныс алу функциясындағы өзгерістерді көрсеткен. Ол өзгерістер өкпенің созылмалы обструктивті ауруымен сырқаттанған пациенттер кіретін топтарға байланысты әртүрлі болып келеді.

*Кілт сөздер:* өкпенің созылмалы обструктивті ауруы, созылмалы бронхит, эмфизема, кеуде клеткасының стандартты рентгенографиясы, спирометрия